Wallstent Experience in Bologna

Gianluca Faggioli

Vascular Surgery
University of Bologna, Italy
Alma Mater Studiorum

Types of Carotid Stents

- Closed cell



Wallstent (BSCI)



Adapt (BSCI)

- Open cell



Precise (Cordis)



Acculink (Guidant)

- Double layer



Roadsaver (Terumo)

C-Guard (Inspire)

Gore Carotid (Gore)

Types of Carotid Stents

- Closed cell



Wallstent (BSCI)



Adapt (BSCI)

- Open cell



Precise (Cordis)



Acculink (Guidant)

- Double layer



Roadsaver (Terumo)

C-Guard (Inspire)

Gore Carotid (Gore)

Types of Carotid Stents

- Closed cell



Wallstent (BSCI)



Adapt (BSCI)

- Open cell



Precise (Cordis)



Acculink (Guidant)

- Double layer

Roadsaver (Terumo)

C-Guard (Inspire)

Gore Carotid (Gore)

Purpose of Carotid Stent

Closed vs. Open Cell

Population	Outcome	*p*-value
Total	All events	0.024
	Post-procedural events	0.002
Symptomatic	All events	0.002
	Post-procedural events	<0.0001
Asymptomatic	All events	1.00
	Post-procedural events	1.00

Bosiers M et al. Eur J Vasc Endovasc Surg 2007

Differences in Stent Behavior

	Closed cell ($n = 305$)	Open cell ($n = 242$)	Hybrid cell ($n = 182$)	p-value
Malapposition[a]	29.8%, (91)	13.2%, (32)	14.8%, (27)	CC vs OC $p < 0.01$ CC vs Hyb $p < 0.01$ OC vs Hyb $p = 0.07$
Plaque prolapse	23.3%, (71)	68.6%, (166)	30.8%, (56)	CC vs OC $p < 0.01$ CC vs Hyb $p = 0.08$ OC vs Hyb $p < 0.01$
Rupture of fibrous cap	24.2%, (74)	43.8%, (106)	39.6%, (72)	CC vs OC $p < 0.01$ CC vs Hyb $p < 0.01$ OC vs Hyb $p = 0.4$

De Donato G et al.
Eur J Vasc Endovasc Surg 20013

Differences in Stent Behavior

	Closed cell ($n = 8655$)	Open cell ($n = 6654$)	Hybrid cell ($n = 5103$)	p-value
Malapposed struts	34.5% (2982)	15% (998)	16.3% (833)	CC vs OC $p < 0.01$ CC vs Hyb $p < 0.01$ OC vs Hyb $p = 0.06$
Embebbed struts	9% (783)	27% (1797)	25.6% (1310)	CC vs OC $p < 0.01$ CC vs Hyb $p < 0.01$ OC vs Hyb $p = 1$
Well apposed struts	56.5% (4890)	58% (3859)	58.1% (2960)	CC vs OC $p = 0.06$ CC vs Hyb $p = 0.08$ OC vs Hyb $p = 1$

De Donato G et al.
Eur J Vasc Endovasc Surg 20013

Rigidity = greater scaffholding

CEA restenosis

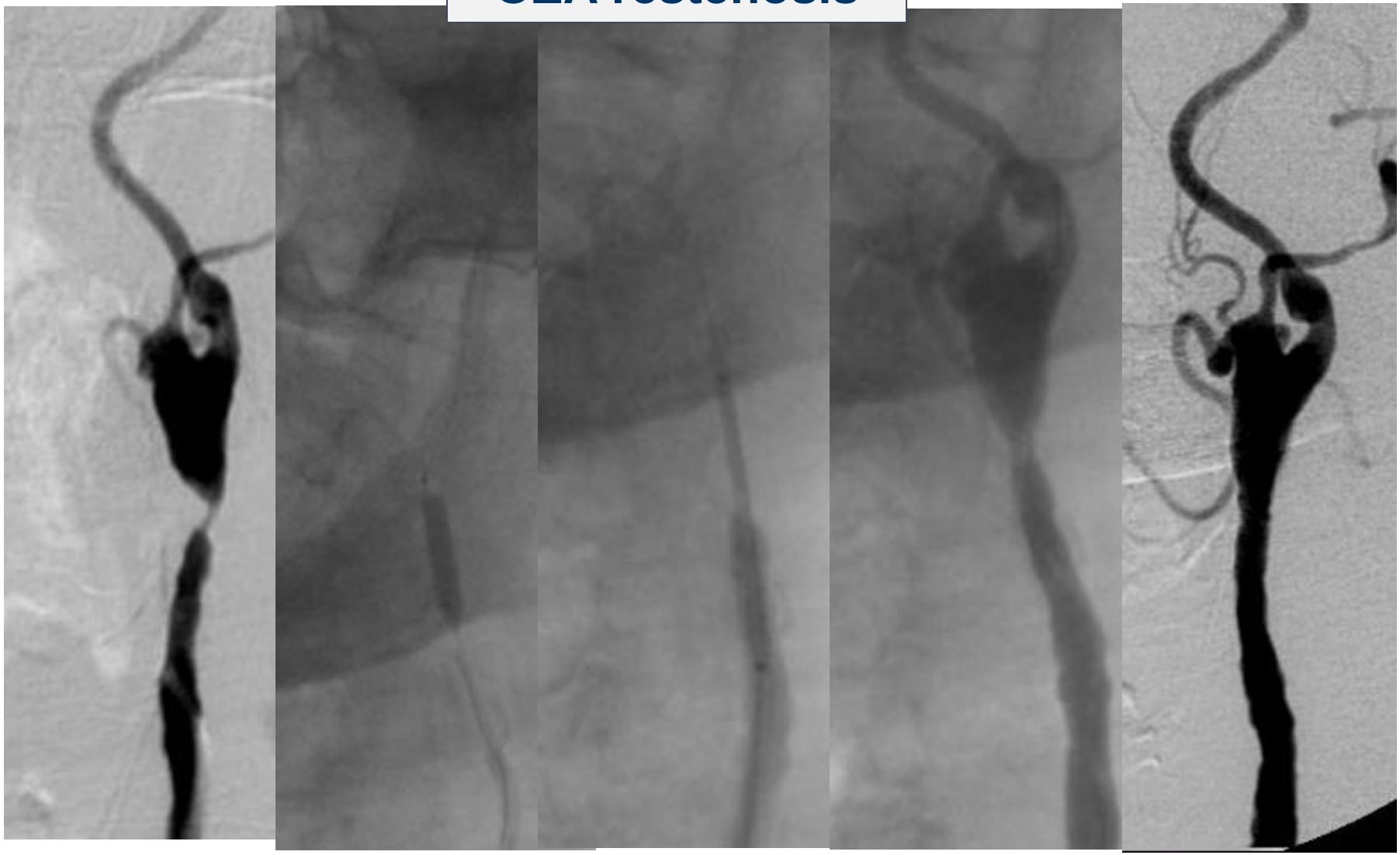

Stenosis and distal pseudoaneurysm

Stenosis and distal pseudoaneurysm

Advanta
5x29

Wallstent
9x30

Intimal flaps after CEA

- TIA I post-op day
- TC-angiography
- no cerebral lesion
- Intimal flap distal to CEA

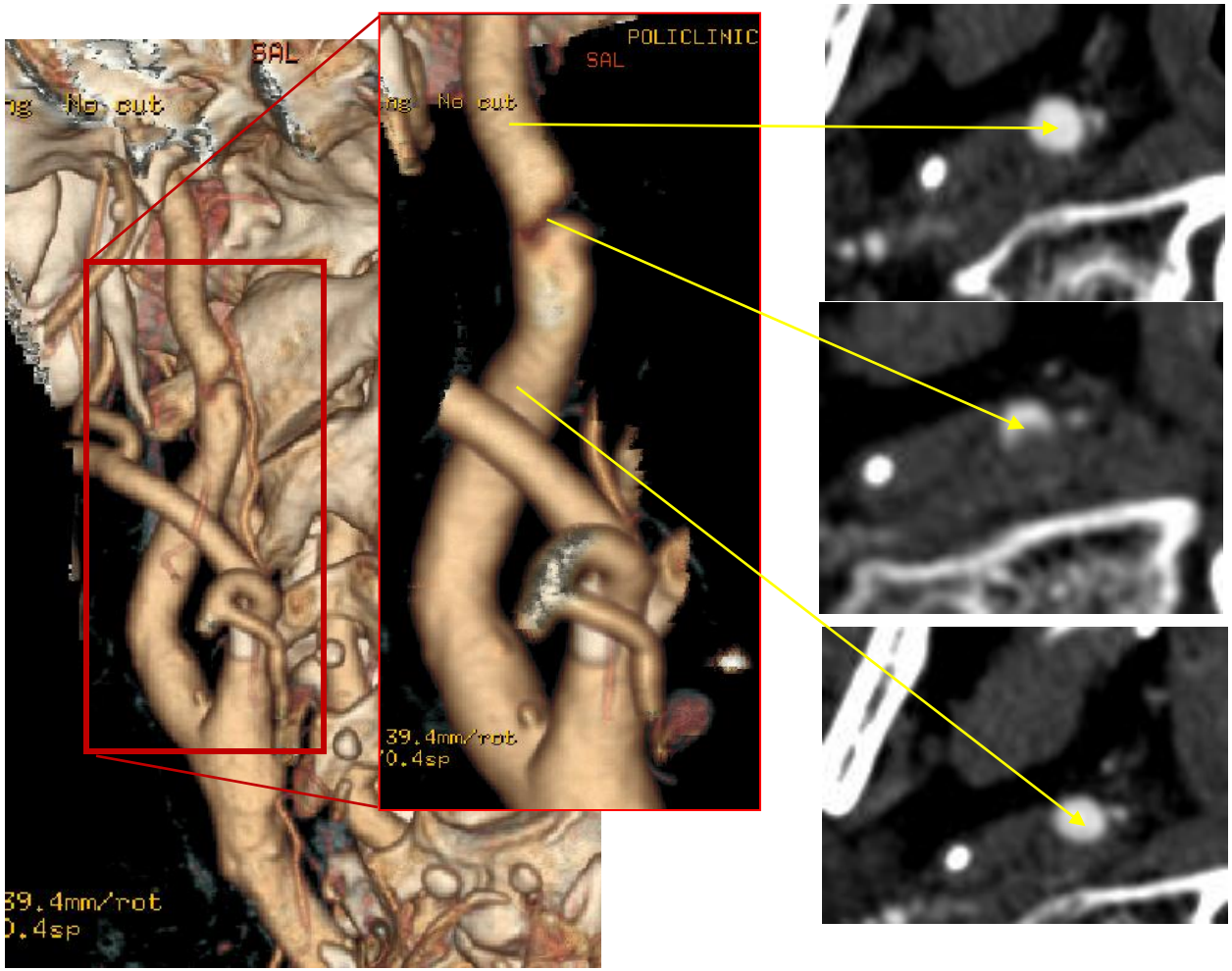

Intimal flaps after CEA

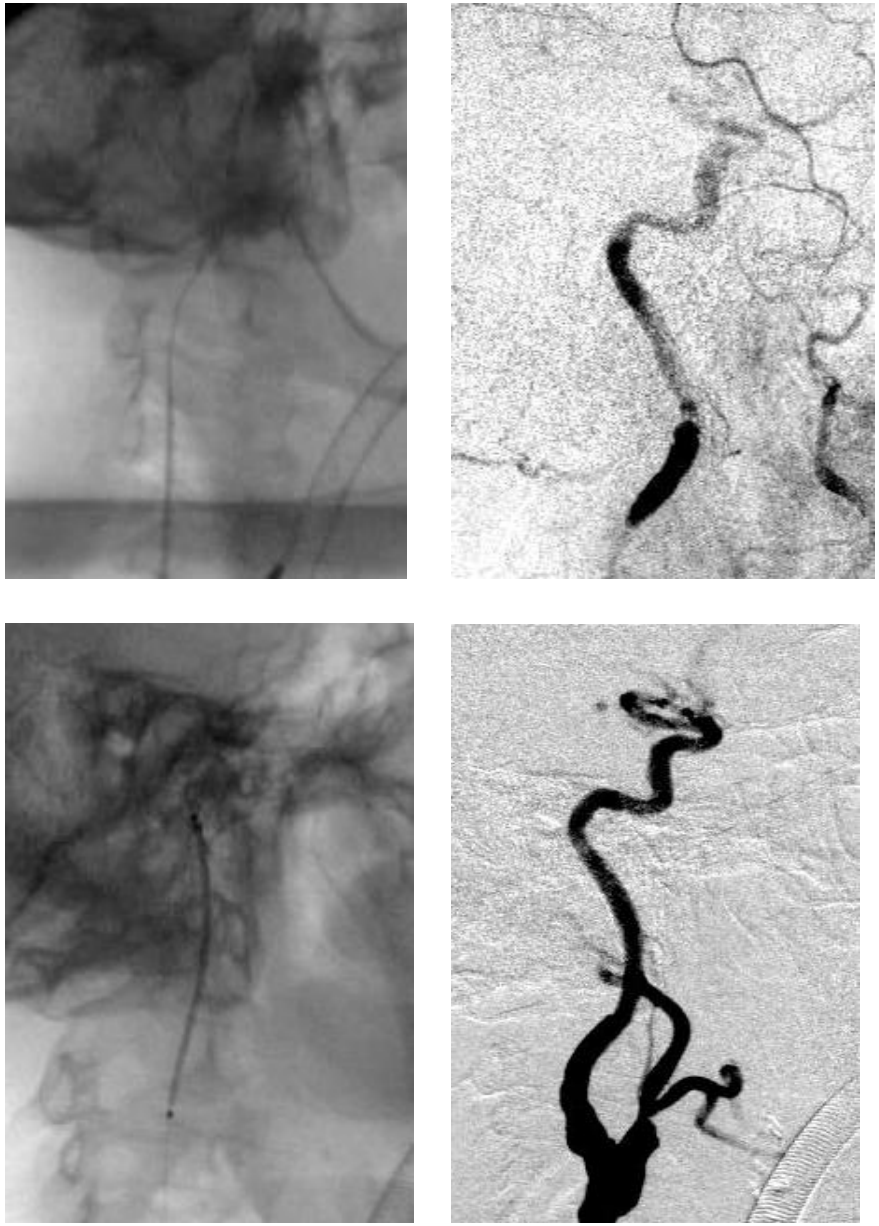

Left Internal Carotid Dissection

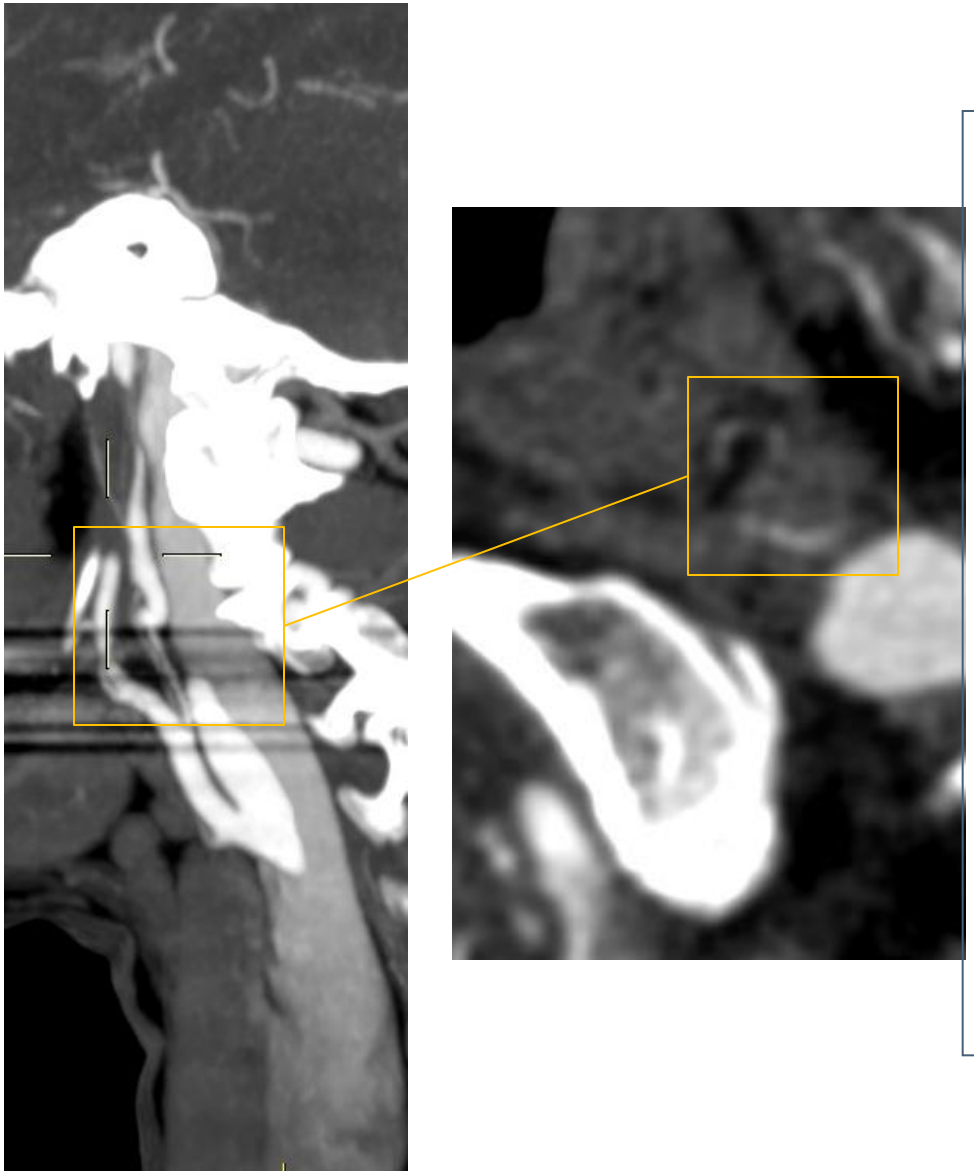

Left Internal Carotid Dissection

- 59 yo female
- No risk factors for ATS
- Progressive worsening of right emiparesis and aphasia despite anticoagulation

Left Internal Carotid Dissection

“Petticoat” technique

- Post Traumatic Internal Carotid Aneurysm Ø 25mm

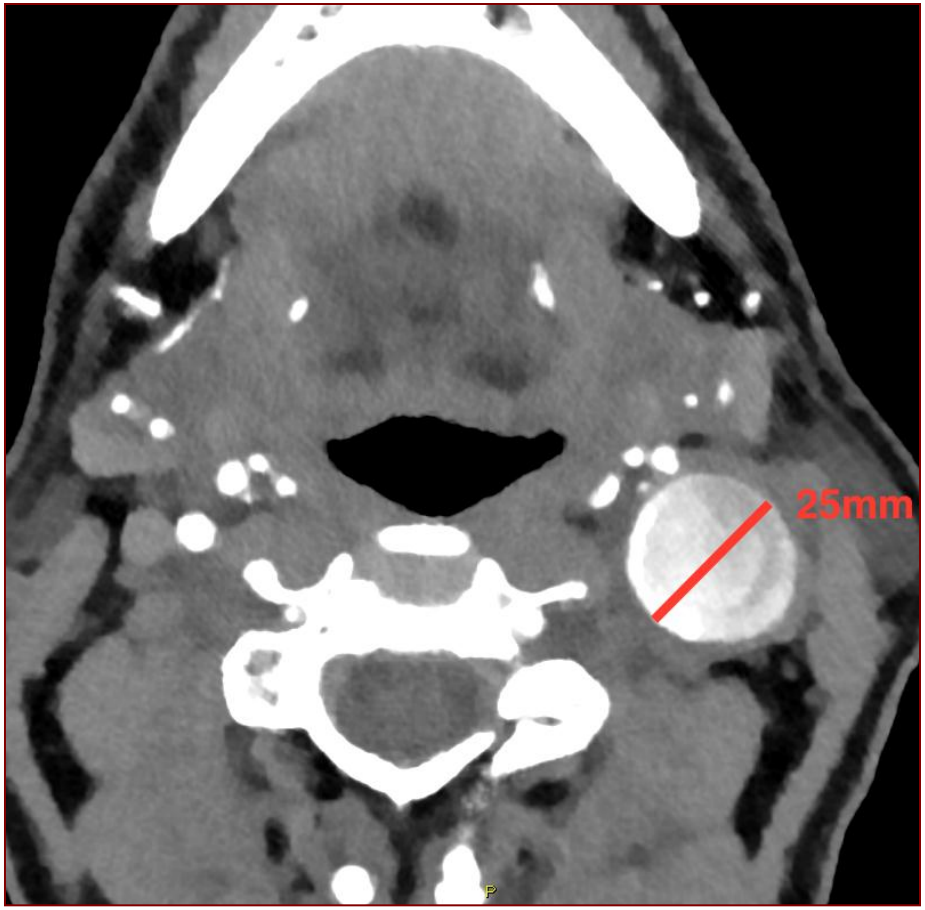

“Petticoat” technique

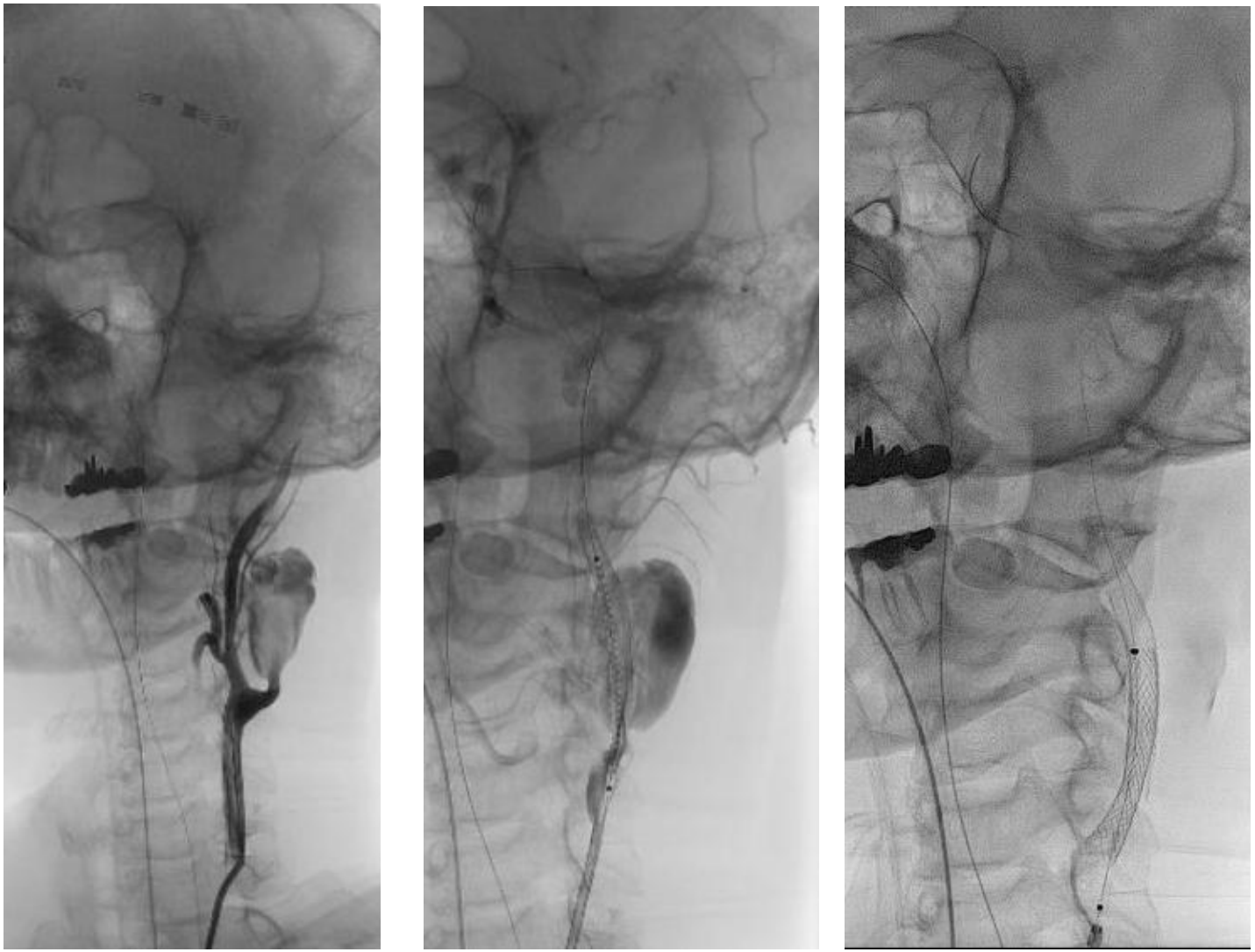

Distal and proximal Gore Viabhan (6x50-7x50)

“Petticoat” technique

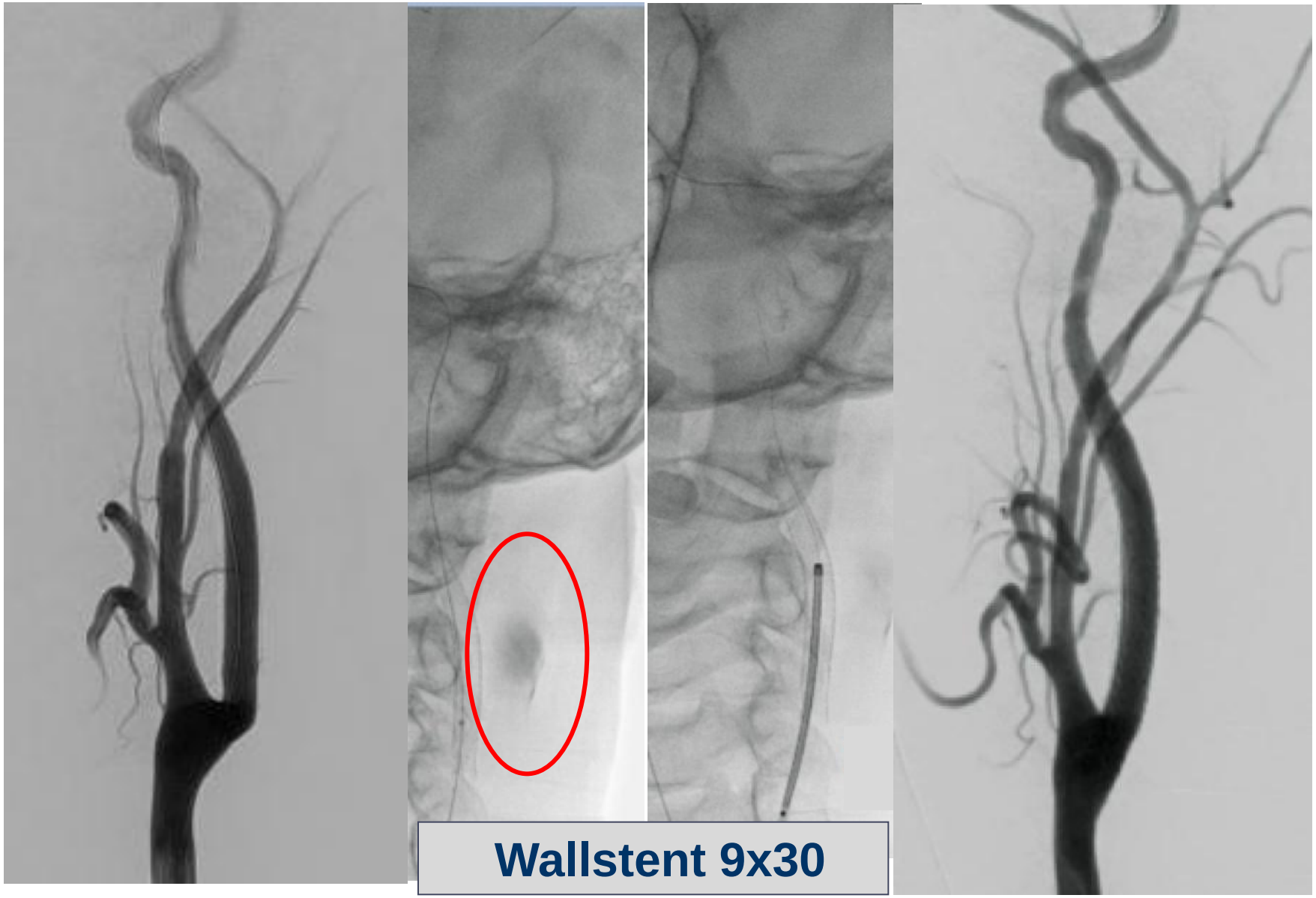

Drawbacks of Closed Cell Design

- Rigid: difficulty in positioning the wallstent in tortuous vessel
- Rigid: slipping of the stent either proximally or distally to the target
- Closed cell design: shortening

Drawbacks of Closed Cell Design

- Rigid: difficulty in positioning the wallstent in tortuous vessel
- Rigid: slipping of the stent either proximally or distally to the target
- Shortening

Drawbacks of Carotid Wallstent: Rigid

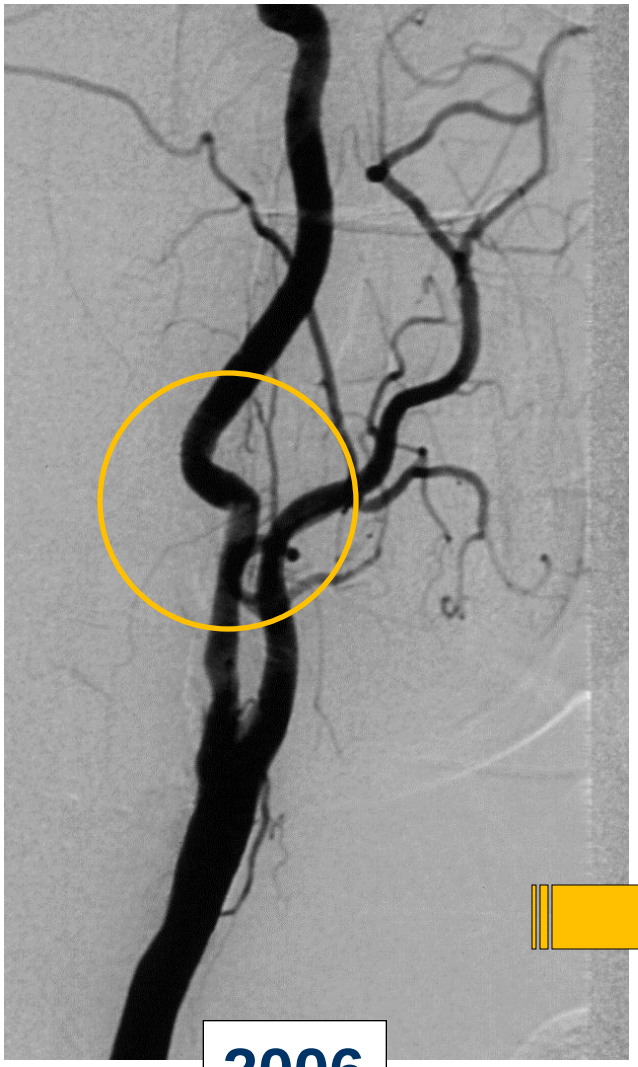

2006

2016

Drawbacks of Carotid Wallstent: Rigid

Drawbacks of Carotid Wallstent: Rigid

Wallstent 7x30

Drawbacks of Closed Cell Design

- Rigid: difficulty in positioning the wallstent in tortuous vessel
- Rigid: slipping of the stent either proximally or distally to the target
- Shortening

Drawbacks of Carotid Wallstent: Shortening

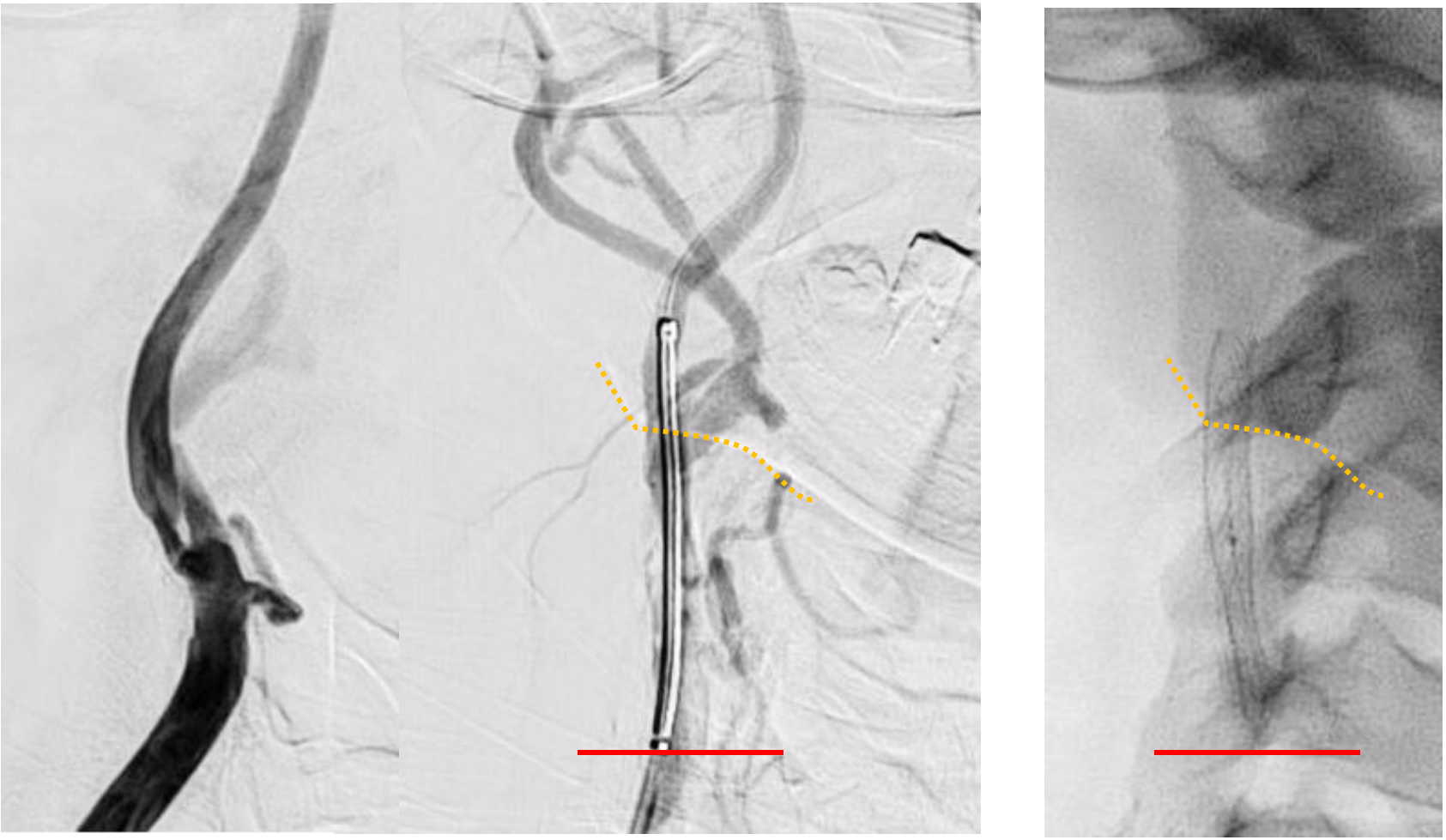

Wallstent 9x30

Drawbacks of Carotid Wallstent: Shortening

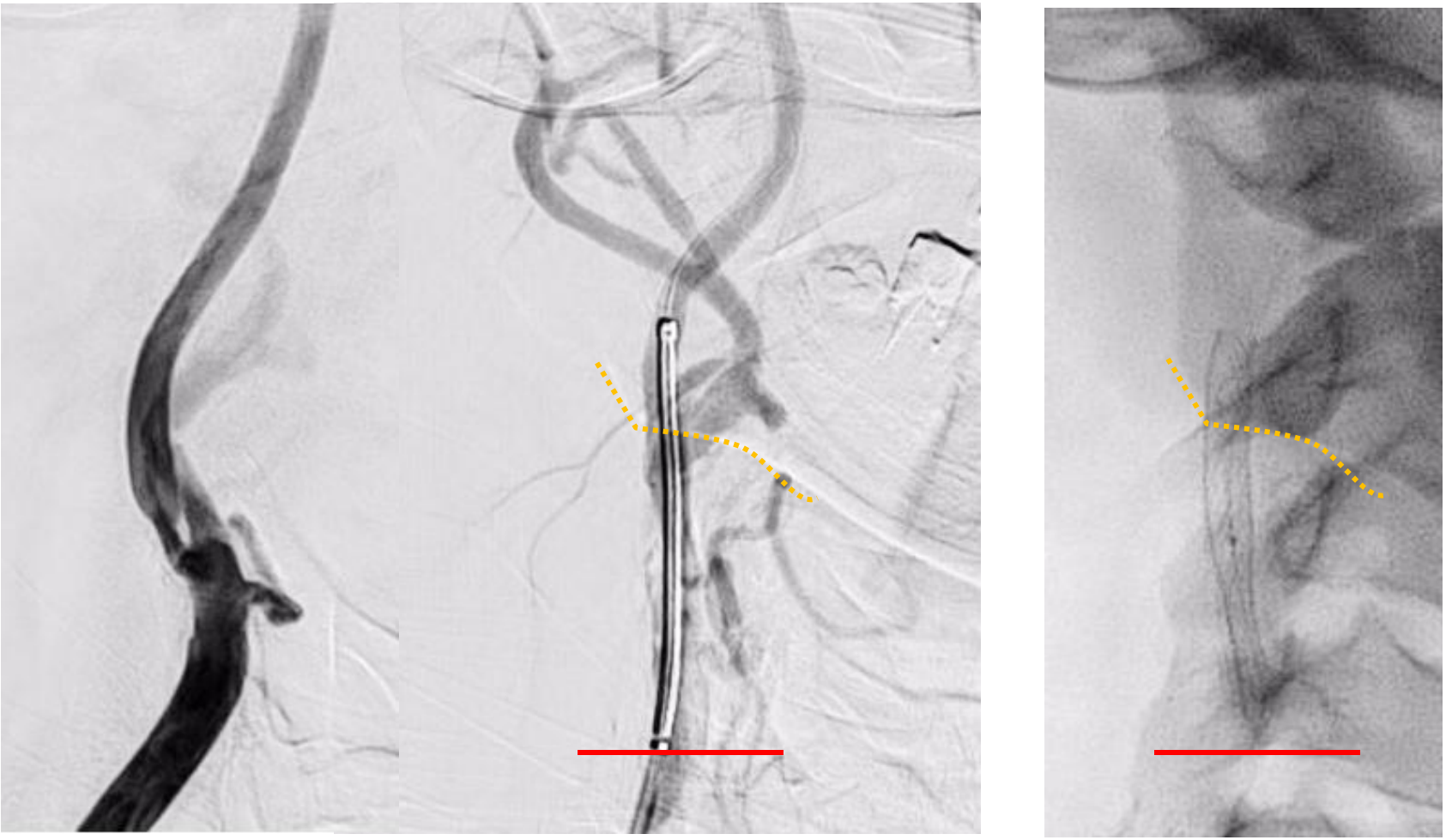

Wallstent 9x30

Drawbacks of Carotid Wallstent: Shortening

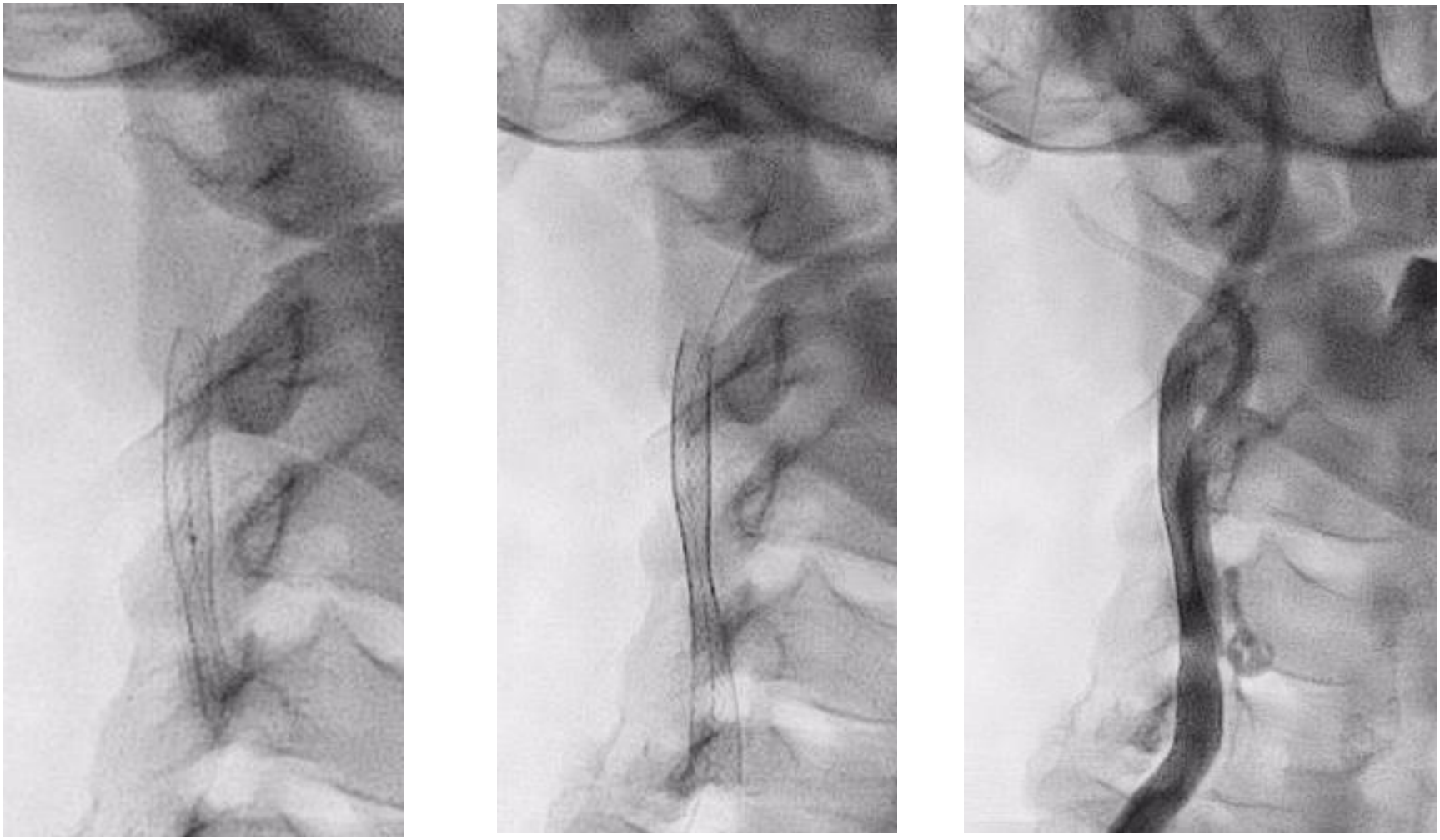

Second Wallstent 9x30

Bologna Experience

- 14 years CAS experience
- 812 endovascular treatment of supra-aortic vessels
- Indication only for asymptomatic, highly selected cases
  - TAO pts
  - Contralateral occlusion
  - Contralateral cord palsy
  - Restenosis

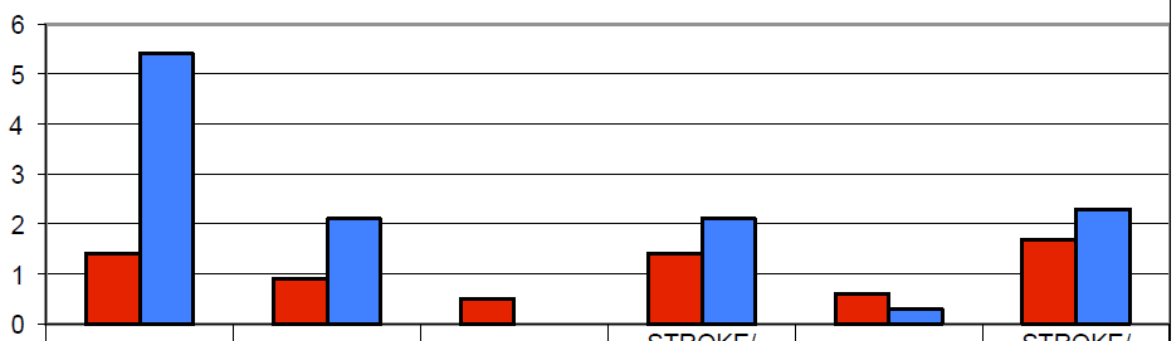

	TIA	STROKE	DEATH	STROKE/ DEATH	MI	STROKE/ DEATH/MI
CEA	1,4	0,9	0,5	1,4	0,6	1,7
CAS	5,4	2,1	0	2,1	0,3	2,3
	P<.001	P=.08	P=.16	P=.37	P=.12	P=.65

Literature Review of Late Wallstent Complications

Journal of Endovascular Therapy
2016, Vol. 23(2) 267–274
© The Author(s) 2016
Reprints and permissions:
sagepub.com/journalsPermissions.nav
DOI: 10.1177/1526602815626558
www.jevt.org
SAGE

Outcomes of 1000 Carotid Wallstent Implantations: Single-Center Experience

Sonia Ronchey, MD[1], Barbara Praquin, MD[1], Matteo Orrico, MD[1], Eugenia Serrao, MD[1], Cristina Ciceroni, MD[1], Vittorio Alberti, MD[1], Stefano Fazzini, MD[1], and Nicola Mangialardi, MD[1]

Abstract

Purpose: To evaluate the outcomes of carotid artery stenting (CAS) with Wallstents in a single-center experience. **Methods:** From January 2003 to December 2013, 1000 carotid artery lesions were treated with Carotid Wallstents under cerebral protection in 877 patients (mean age 71.7±8 years; 621 men). Indications for treatment were de novo lesions (>70% asymptomatic and >60% symptomatic); stenoses following carotid endarterectomy, radiation, or neck surgery; contralateral laryngeal nerve palsy; and high surgical risk. All the patients underwent duplex ultrasound and clinical evaluation during follow-up; radiography was performed when fracture or stent migration was suggested by ultrasound. **Results:** Procedure success was achieved in 99.3% of patients. Major and minor 30-day adverse events occurred in 2.1% of patients, including stroke (1.8%: 1.3% minor, 0.5% major), myocardial infarction (0.1%), and death (0.2%). Plaque morphology, nature of stenosis, and symptomatic status were significantly associated with the risk of postoperative neurologic events. Restenosis occurred in 3.2% at a mean 45.5-month follow-up and was significantly associated with diabetes, smoking, symptomatic stenosis, de novo stenosis, and calcification (plaque III/IV). No fracture or migration was registered during follow-up. **Conclusion:** CAS is a valid method for treating carotid artery disease, with very low rates of major adverse events and neurologic complications. The Carotid Wallstent seems to have excellent results, even with complex plaque morphology, and a low incidence of restenosis at follow-up.

Literature Review of Late Wallstent Complications

Author	Year	N cases	Type of complication
Akgul et al.	2007	1	Displacement of marker ring
Yoon et al.	2009	4	Proximal shortening
Myouchin et al.	2013	2	Unsuccessful placement
Zhao et al.	2013	1	Proximal Shortening
Garriboli and Jannello	2015	1	Proximal shortening

Wallstent: Overall Analysis

- Plaque coverage
- Rigid
- Very rare late complications
- Highly reliable and user friendly